

Comparing Arthroscopic Bankart repair and Latarjet procedure in treating anterior shoulder instability in high demand patients

¹Ahmed Mohamed Hany Mohamed Farid Genena, ²Mohammed Hassan Aly Hashem, ³Ahmed Hassan Waly, ⁴Mohamed Osama Hegazy

¹MBBCh - MSc in Orthopaedic Surgery and traumatology

²Assistant Professor of Orthopaedic Surgery and traumatology, Faculty of Medicine, Helwan University

³Professor of Orthopaedic Surgery and traumatology, Faculty of Medicine, Alexandria University

⁴ Professor of Orthopaedic Surgery and traumatology Faculty of Medicine, Benha University

DOI: <https://doi.org/10.5281/zenodo.7515368>

Published Date: 09-January-2023

Abstract: Aim of the study: Compare the results of Latarjet operation and Arthroscopic Bankart repair in high demand patients including heavy labour and contact athletes with traumatic anterior shoulder instability. **Methodology:** Design: This is a prospective study of high demand patients with traumatic anterior shoulder instability selected during the period between February 2019 and July 2020. Thirty patients met the inclusion criteria, half of them underwent arthroscopic bankart repair, while the other half had an open Latarjet surgery. All patients were followed up for at least 6 months. **Methods of treatment:** A) Arthroscopic Bankart repair procedure & B) Open Latarjet Procedure: **Result:** The main finding of our study was the time to return to work/sports which was significantly lower in the Latarjet group (5.2 months) compared to the Bankart group (7 months). On the other hand, there was no statistical significance between the rates of return to sports/work in both groups. All patients in our study were assessed according to the Rowe scoring system as regards stability, ROM and function of the shoulder. There was a statistically significant increase in the Rowe score postoperatively with mean score of 84.0 ± 15.83 compared to 27.17 ± 12.15 preoperatively. However, there was no statistical significant difference in the postoperative ROM and Rowe score between Bankart and Latarjet groups. **Conclusion:** Both the Latarjet procedure and the arthroscopic Bankart repair revealed satisfactory clinical outcomes with nearly similar rate of return to sports/work in high demand patients with recurrent anterior glenohumeral dislocation. Latarjet procedure is considered more invasive and non-anatomical procedure, however it is less costly with shorter time to return to sports/work compared to Bankart. Evidence-based data support both procedures, thus the personal preference of the surgeon will always play a paramount role in choosing one of these procedures over the other.

Keywords: Bankart repair, Latarjet procedure, shoulders instability.

1. INTRODUCTION

Shoulder joint is the most mobile joint in our body; its significant range of motion makes it highly susceptible to dislocation. Shoulder dislocation represents 50% of all joint dislocations, especially in young population.(1)

Anterior glenohumeral instability represents a common complaint in the athletic, young population, with a rate of 12 dislocations per 100,000.(2)

In addition, athletes taking part in collision or contact sports are more prone to high-velocity impacts and positions making their shoulders susceptible to injury in comparison to non-contact athletes.(3)

The surgical management of recurrent instability was firstly described by Bankart in 1938.(4) Open Bankart stabilization was considered the gold standard with early studies showing better results compared to arthroscopic stabilization.(5, 6) However, arthroscopic techniques and equipment have been evolving and arthroscopic repair with suture anchors now attains equivalent results to open repair in the treatment of bankart lesions.(7)

Recently, with better understanding of the pathoanatomic changes with recurrent shoulder instability, focus has been shifted toward soft tissue versus bony stabilization procedures.(8)

Humeral and/or glenoid bone lesions have been demonstrated to occur in 90% to 95% of shoulders with recurrent instability.(9) Failure to treat these bony defects can lead to a poor outcome. A bony glenoid defect of 21% has been shown to jeopardize shoulder stability.(10)

Michel Latarjet (11) represented his technique for shoulder stabilization in 1954, in which transposed the horizontal limb of the coracoid process to the anteroinferior rim of the glenoid via a split in the subscapularis muscle and fixed it with one screw. The Latarjet-Patte procedure is a modification of this technique using 2 screws instead of one as well as repairing the anterior capsule to the remaining stump of the coracoacromial ligament.(12)

The osteotomized tip of the coracoid process is passed through the subscapularis split and fixed on the glenoid neck.

The Latarjet-Patte procedure addresses both soft tissue and bony deficiencies. The coracoid graft is used to restore the glenoid's anteroposterior diameter, thus increasing the stability in addition to preventing the engaging Hill-Sachs lesion from levering on a deficient antero-inferior glenoid rim.(14) The sling effect is considered the main stabilizing mechanism which involves the interaction between the lower part of the subscapularis and the conjoint tendon with the arm in abduction and external rotation.(15 (

Evidence-based data support the efficacy of both procedures; arthroscopic bankart and Latarjet, and the surgeon's preference plays a major role in choosing one of these procedures over the other. Supporters of Latarjet procedure defend their choice based on the lower rate of recurrence and shorter time to return to the patients' preinjury sport levels. On the other hand, arthroscopic bankart restores the normal shoulder anatomy of the shoulder as well as maintains the range of motion (ROM).(16)

The Latarjet procedure has proved to be effective in dealing with recurrent anterior shoulder instability with severe glenoid bone loss, as a primary and revision procedure.(17) However, there is scant information in the literature in terms of complications and functional results in competitive athletes.(18,19)

Competitive athletes represent an exceptional challenge for shoulder surgeons. Early return to the pre-injury level with minimal rate of recurrence is considered one of the major expectations of competitive athletes. Therefore, choosing the surgical procedure for these high demand patients should aim toward achieving a stable shoulder in a timely return to sports.(20)

Aim of the Work / Objectives

Compare the results of Latarjet operation and Arthroscopic Bankart repair in high demand patients including heavy labour and contact athletes with traumatic anterior shoulder instability.

2. PATIENTS AND METHODS

This is a prospective study of high demand patients with traumatic anterior shoulder instability selected during the period between February 2019 and July 2020. Thirty patients met the inclusion criteria, half of them underwent arthroscopic bankart repair, while the other half had an open Latarjet surgery. All patients were followed up for at least 6 months.

Inclusion criteria

- Traumatic anterior shoulder instability.
- High demand patients (Contact sports athletes and heavy labour workers).
- Age group from 18 to 45 years.

Exclusion criteria

- Patients with multidirectional instability.
- Bilateral shoulder dislocation.
- Low demand patients.
- Patients with gleno-humeral dysplasia.
- Patients with associated rotator cuff tear.
- Patients with associated fracture of the greater tuberosity or the proximal humerus.
- Paralytic dislocation.
- Patients with hyperlaxity (scoring >5 according to Beighton score).
- Glenoid bone loss > 15% of glenoid width
- Hill-Sachs lesion > 20% of humeral articular arc
- Patient who previously underwent ipsilateral shoulder surgery for instability

Clinical Evaluation**1) History**

- Personal data: Name, Age, Sex, Occupation, Address, Hand Dominance.
- Past History: Presence of previous episodes of instability, Number of episodes, Age at which first episode occurred, Mechanism of initial injury (minimal or high energy, traumatic or atraumatic), Position and ease of relocation after each event, Duration of immobilization and any subsequent rehabilitation, Previous surgical management.
- Present History: Pain (On exertion, during daily activities, at rest), Limitation of activity & difficulty at work.
- Medical & Surgical History

2) Clinical Examination

- Overall evaluation of the musculoskeletal system
- Examination of the cervical spine are required to exclude spinal disorders that may present with shoulder pain
- Shoulder examination:

- Inspection
- Palpation
- Assessment of the ROM as well as muscle strength
- Specific tests and signs which may be helpful in diagnosing recurrent traumatic anterior shoulder dislocation:

- 1) Anterior Drawer test
- 2) Apprehension test and its modifications (Relocation and Release test)
- 3) Sulcus test
- 4) Rotator cuff examination.

Scoring system

All patients were assessed pre and post-operatively according to the Rowe scoring system as regards stability, motion and function of the shoulder.

The Rowe et al Shoulder Outcome Score:(117)

International Journal of Novel Research in Life Sciences

Vol. 10, Issue 1, pp: (1-22), Month: January - February 2023, Available at: www.noveltyjournals.com

The Rowe Score is a 100 point functional assessment tool of the shoulder in which high scores represents increased function.

It combines three separate subscales:

Stability (50)

50: No recurrence

30: Apprehension in specific positions

10: Subluxation

0 : Recurrent dislocation

Motion (20)

20: 100% External Rotation, Internal Rotation and Elevation.

15: 75% External Rotation, Internal Rotation and Elevation.

5: 50% External Rotation, 75 % Internal Rotation and Elevation.

0: 50% Elevation, Internal Rotation ; no External Rotation.

Function (30)

30: No limitation(work\sport) ; no pain

20: Minimal limitation with minimal discomfort

10: Moderate limitation with discomfort

0: Marked limitation with pain

The maximum score possible is 100-points, score between 90 and 100 is considered as excellent, 75 to 89 points is considered as good, 51 to 74 points is considered as fair and 0 to 50 points is considered as poor.

Investigations:

- Routine laboratory tests
- Radiological examination
 - Antero-posterior X-rays of the shoulder
 - CT of the shoulder

CT scan was performed for all patients including 3-D reconstruction with subtraction of the humeral head with an “en face” view of the glenoid. Glenoid bony loss was measured on the “en face” view of the 3-D CT using best fit circle method of affected shoulder.

- MRI of the shoulder

It accurately showed anterior labro-ligamentous lesions (Bankart lesion). It was also used to exclude other soft tissue injuries, which can occur with recurrent anterior instability like rotator cuff injury, subscapularis rupture, and biceps tendon pathology. Size of Hill-Sachs defect was calculated as a percentage of articular arc loss on axial MRI.

In our study, no patient had glenoid bony loss >15% of the glenoid width, and no patient had HSL more than 20% of the articular arc.

Methods of treatment

A) Arthroscopic Bankart repair procedure:

- Anaesthesia

All patients received general anaesthesia with hypotensive measures. Prophylactic antibiotic was administered.

Position

Patients were positioned in the beach chair position. The back of the bed is raised to around 60 degrees and the patient is positioned such that the medial aspect of their scapula is at the border of the bed. Next, the head is secured.

The patient's buttocks should be secured against the bed without any gap between the operating table and the patient. Multiple pillows or a large pad can be put underneath the legs of the patient. Once the patient is adequately positioned, a safety belt is applied to secure the patient properly to the table.

Compression devices or elastic stocking are put on both lower limbs to prevent from venous thromboembolism.

Disinfection and draping is done allowing free motion of the limb.

Arthroscopy stack is positioned on the other side of the operating table close enough to the operating table to ensure there is plenty of slack in all cables and tubing.

Pump pressure is initially set to around 40 mmHg, using normal saline in addition to 1:1000 epinephrine (1 ml for every 5 litre fluid bag).

Beach chair position.

Examination under anaesthesia

All patient were examined under anaesthesia before starting the procedure to assess the direction and degree of the glenohumeral translation.

Procedure

A standard posterior viewing portal is established 2 cm distal and 1cm medial to the postero-lateral corner of the acromion, parallel to the glenohumeral joint. Then, the antero-superior portal is done under arthroscopic guidance superior and lateral to the coracoid bone such that it goes through the rotator interval and access the joint at the biceps tendon insertion onto the labrum superiorly.

Then, 2nd anterior portal is created at the superior border of the subscapularis so that the anchors can be inserted into the inferior glenoid. It is crucial to leave a 3cm interval inbetween the two anterior portals for adequate working space. An 8 mm corkscrew cannula may be useful to ensure the easy introduction of instruments into the intra-articular space. Diagnostic arthroscopy is then performed and the bankart lesion is assessed. (Fig.50)

Arthroscopic view of the right shoulder using posterior visualizing portal showing Bankart lesion.

Glenoid Preparation

Elevation and freeing up of the labrum is done arthroscopically using tissue liberator as it is often scarred down to the anterior glenoid in a nonanatomic, medialized position. Then, grasper is used to pull the labro-ligamentous complex to the articular margin (into its normal position) while capsular tension and mobility are evaluated. This is a crucial step as inadequate mobilization of the labrum from the neck of the glenoid may end up with a non-anatomic, less functional repair. Also, when this scarred tissue is adequately elevated off the glenoid neck, the subscapularis muscle could be easily seen anteriorly.

The scapular neck and the glenoid rim are then abraded to establish a bleeding surface using an arthroscopic shaver, burr, or rasp.

Glenoid preparation.

Anchor Placement and Capsulo-labral Plication

As viewing via the posterior portal, drill guide for the anchor (Jugger Knot (ZIMMER BIOMET) all suture 1.5mm anchor) is passed through the antero-inferior portal and is positioned on the glenoid as close as possible to the 6 o'clock position.

Anchors are then placed 1–2mm onto the articular cartilage surface. Inserting the anchor far too medially will end up with a mal-reduced labrum off the glenoid.

Inserting the anchor far onto the articular margin will risk skiving underneath the articular cartilage and developing a chondral flap. The trochar is positioned almost 45° to the glenoid surface.

A drill is used to create the pilot hole, and then the anchor is tapped into the hole.

Then, one limb of anchor sutures is grasped by the grasper and pulled out via the antero-superior portal.

The capsulo-labral tissue is then captured with a curved suture passer (lasso) loaded with a no. 1 polydioxanone(PDS) suture. The aim is to grab a healthy bite of the capsule inferior to the suture anchor trying to shift the soft tissue superiorly, thus reducing the capsular volume. The PDS suture is advanced out of the suture passer and into the joint, where it is then grasped and pulled-out of the antero-superior portal. A simple loop is made with the PDS suture that is pulled out of antero-superior portal and loaded with the suture of the anchor and then cinched down by removing the suture passer and pulling the PDS limb through antero-inferior portal shuttling the limb of the suture via the tissue and out of the antero-inferior portal.

Anchor placement with sutures directly in the articular cartilage margin then capsulo-labral tissue is captured with a curved suture passer.

Knot Tying and Anchor Placement

A sliding knot followed by locking half hitches are applied with care to choose the limb that passed through the tissues to be the post to deliver the knot far away from the articular surface rather than towards it to avoid the injury of the articular cartilage with the suture.

Suture tails are then cut with arthroscopic cutters, leaving behind a small 2mm tail.

Following anchors are inserted in similar fashion at 7.30 and 8.30o'clock positions (left shoulder).

Final view after repair with 3 anchors.

Skin Closure and Immobilization of the shoulder

Skin is closed with non-absorbable sutures and sterile dressing is applied.

Arm is then put in a shoulder immobilizer with a strap fastened around the waist.

Open Latarjet Procedure:

Anaesthesia

All patients received general anaesthesia with hypotensive measures. Prophylactic antibiotic was administered.

Position

All patients were positioned in the low beach chair position (the back of the bed is lifted to approximately 40 degrees). The arm is freely draped to allow intra-operative manipulation of the upper limb, especially external rotation and abduction.

Figure 54: Low beach chair position of the patient with the arm draped free.

Examination under anaesthesia

All patients were examined under anaesthesia before starting the procedure to assess the direction and the direction of the gleno-humeral translation.

Procedure

Surgical approach

5-7 cm incision starting from the coracoid process directed downwards to the axillary fold.

Skin incision starting from tip of coracoid process to the axillary fold.

□ A delto-pectoral approach is used, the deltopectoral interval is located and the cephalic vein is identified. The deltoid muscle and the cephalic vein are retracted to the lateral side exposing the conjoint tendon. Meticulous haemostasis is maintained all through the approach. Self-retaining retractors are used to keep the interval between the pectoralis major and the deltoid. Moreover, a Hohmann retractor is inserted above the coracoid to improve the exposure.

Coracoid process and conjoint tendon exposure.

Coracoid Graft Harvest and Preparation

□ With the shoulder in abduction and external rotation, the coraco-acromial ligament (CAL) is best exposed and incised with electrocautery from its attachment to the coracoid, the coraco-humeral ligament, located under the CAL, is released and then the arm is placed in internal rotation and adduction to improve the visualisation on the medial side of the coracoid and the pectoralis minor muscle is detached from the medial surface of the coracoid process.

□ A coracoid osteotomy is performed just anterior to the insertion of the coraco-clavicular ligament at the base of the coracoid using a 90 degree oscillating saw (from medial to lateral) or a curved osteotome.

Coracoid osteotomy using an oscillating saw (left) or a curved osteotome (right)

□ The coracoid graft is then held gently using the grasping forceps at the level of the incision. Soft tissue is stripped off the inferior surface of the coracoid by electrocautery. The inferior surface of the coracoid is then decorticated using the oscillating saw, exposing a flat broad cancellous bone.

Decortication of the inferior surface of the coracoid graft.

□ An osteotome is put beneath the coracoid graft to protect the skin and then 2 holes are drilled using a 2.7-mm drill, the holes are positioned in the central axis of the graft and almost 1cm apart.

Drilling the two holes in the coracoid graft.

Glenoid Exposure and Preparation

□ with the arm adducted and externally rotated, the subscapularis muscle is exposed. The subscapularis is then split at the junction of the superior two thirds and the inferior one third.

□ The capsule is incised vertically at the level of the joint line, retractor is then inserted into the gleno-humeral joint thus exposing the antero-inferior aspect of the glenoid.

Subscapularis splitting + vertical incision of the capsule.

□ The antero-inferior labrum and periosteum are excised with electrocautery, the anterior surface of the glenoid is decorticated with an osteotome. The goal is to provide a flat bleeding surface of cancellous bone to put the graft on.

Coracoid Positioning & Fixation

□ The longitudinal axis of the prepared coracoid graft is then positioned supero-inferiorly along the neck of the glenoid in line with the articular surface to ensure it is neither too far medial nor too far lateral, resulting in coracoid overhang. The optimal position is between the 3 and 5 o'clock on the glenoid.

□ A 1.25-mm guidewire is then inserted through the inferior hole of the coracoid to hold the position of the graft. The position of the coracoid graft is then evaluated. If it was acceptable, a second 1.25-mm guidewire is then inserted through the superior hole and the final position was again evaluated. The 2.7-mm cannulated drill bit is then used to drill the inferior hole bicortically into the glenoid, a 35mm long 3.5 cannulated screw is typically inserted in the inferior hole and intraarticular inspection is done to ensure that the screw is not penetrating glenoid articular cartilage.

□ The 2.7-mm cannulated drill bit is then used to drill the superior holes in the glenoid and a second 3.5 cannulated screw is inserted.

Figure 61: Final position of the graft in flush with the glenoid.

Skin Closure and Shoulder immobilization

- The stump of the CAL is repaired using sutures to the capsule. Then, subscapularis split is closed by absorbable sutures. The remainder of the wound is closed in layers.
- Arm is then put in a shoulder immobilizer with a strap fastened around the waist.

Postoperative Rehabilitation

Shoulder immobilizer is kept for 5 weeks.

Phase 1 (week 0-5) aim is protecting the anatomic repair/bony augmentation, avoiding the negative results of immobilization, improving proprioception and dynamic stability, and minimising inflammation and pain. Passive and assisted active ROM exercises are started, but avoiding abduction above 90 degrees, active external rotation, or extension.

Phase 2 (week 6-12) aim is to regain full ROM gradually, restore muscle strength, and enhance neuromuscular control. Additional aggressive muscle strengthening and ROM are advanced to meet the patient’s functional demands.

Phase 3 (week 13-20) aim is to improve the muscle strength, endurance, and power and to initiate the functional activities gradually.

Lastly, the phase of return to activity (month 5-9) aim is to return gradually to sport activities meanwhile maintaining mobility, strength and stability.

3. RESULTS

Statistical analysis of the data

Data were analysed using the IBM SPSS software package Version 20.0 (Armonk, NY : IBM Corp).

Qualitative data were expressed in number and percent. Quantitative data were reported using range (minimum and maximum), standard deviation, mean, median and interquartile range (IQR). Significance of the results was judged at the 5% level.

Demographic data

From February 2019 to July 2020, thirty patients with recurrent anterior glenohumeral dislocation met the inclusion criteria. Fifteen of them underwent arthroscopic Bankart repair procedure and the other fifteen underwent open Latarjet procedure. The mean duration of follow up in our study was 9.27 months ±2.70 (range, 6-20 months). All patients were males and with mean age at surgery of 28.6 years (range, 18-41 years).

There were 27 dominant (90%) and three non- dominant (10%) shoulders. The mean number of preoperative dislocation episodes was 6 (range, 2-12 times).

21 patients were heavy labour (70%), 5 were recreational athletes (13.2%) and 4 (16.6%) professional athletes.

The mechanism of first dislocation was direct trauma in 12 patients (40%) and indirect trauma in 18 patients (60%).

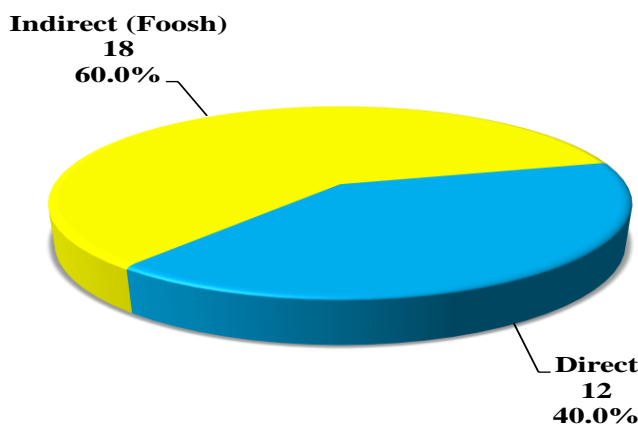


Figure 1: Distribution of the studied cases according to mechanism of first dislocation.

Reduction of the first shoulder dislocation was done with anaesthesia in 21 cases and without anaesthesia in 9 cases.

Post reduction, immobilization in arm sling followed by physiotherapy was achieved in 5 patients. Immobilization without physiotherapy in 19 patients and no immobilization in 6 cases.

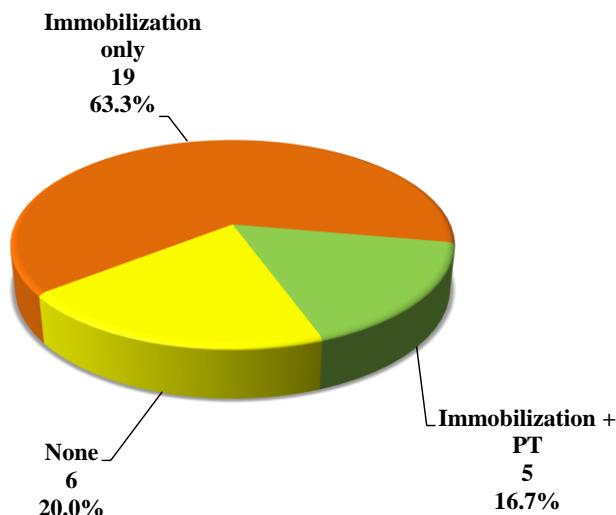


Figure 2: Distribution of the studied cases according to post reduction immobilization and physiotherapy.

A) Pre-operative evaluation

1. Pre-operative ROM

Table 1 and 2 shows the pre-operative shoulder ROM of the Bankart group and the Latarjet group respectively.

Table 1: The pre-operative ROM of the Bankart group

Bankart	Forward flexion	ER in 90 ° Abduction	IR in 90 ° Abduction
MEAN	170°	75°	75°
RANGE	125-180°	50-100°	65-90°

Table 2: The pre-operative ROM of the Latarjet group.

Latarjet	Forward Flexion	ER in 90 ° Abduction	IR in 90 ° Abduction
MEAN	165°	75°	80°
RANGE	120-180°	50-100°	65-90°

2. Pre-operative Rowe score

All patients were assessed according to the Rowe scoring system as regards stability, motion and function of the shoulder.

The pre-operative Rowe score ranged from 5 to 50 with mean score of 27.17 ±12.15.

a- Preoperative function

Seven patients (23.3%) had marked limitation and pain. Sixteen patients (53.3%) had moderate limitation and discomfort. Five patients (16.7%) had minimal limitation and minimal discomfort. Two patients (6.7%) had no limitation and no pain. The mean was 10.67 within the range of 0-30 points.

b- Pre-operative stability

All patients (100%) had recurrent dislocations scoring 0 out of 50 points.

c- Pre-operative range of motion

Seventeen patients (56.7%) had full range of motion. Nine patients (30%) had 75% ER, IR and elevation. Four patients (13.3%) had 50% ER, 75% IR and elevation. The mean was 16.5 within the range of 5-20 points.

A) Comparison between the Bankart and the Latarjet groups.

1. Range of motion

There was no statistically significant difference between mean post-operative forward flexion, external rotation in 90° abduction and internal rotation in 90° abduction between both groups; Bankart repair and Latarjet.

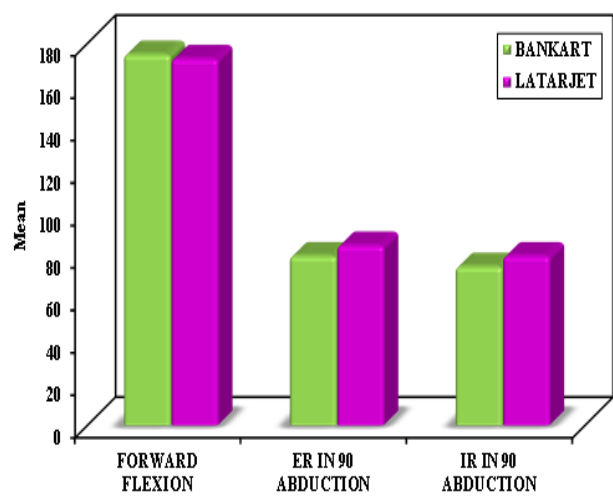


Figure 3: Comparison between the two studied groups according to the postoperative range of motion.

2. Rowe score:

The overall mean for the Rowe score in the 30 patients increased from 27.17 ±12.15 points preoperatively to 84.0 ±15 points post-operatively which was statistically significant.

Pre-operatively all 30 patients were considered poor (scoring 0-50). Post-operatively 14 patients (46.6%) were excellent (scoring 90-100), 12 patients (40%) were good (75-89), 2 patients (6.7%) were fair (51- 74) and 2 patients were poor (0-50).

a- Postoperative function:

Sixteen patients (53.3%) had no limitation and no pain. Nine patients (30%) had minimal limitation and minimal discomfort. Five patients (16.7%) had moderate limitation and discomfort. The mean has increased from 10.67 to 23.67 which is statistically significant.

b- Post-operative stability:

Twenty patients (66.7%) had no recurrence. Ten patients (33.7%) had positive apprehension in certain positions. The mean has increased to 42.33 which is statistically significant.

c- Post-operative range of motion:

Twenty patients (66.7%) had a full ROM.

Nine patients (30%) had 75% ER, IR and elevation. One patient (3.3%) had 50% ER, 75% IR and elevation. The mean has increased from 16.5 to 18.0 which is statistically significant.

There was no statistically significant difference between the mean post-operative (Final Rowe score, function, stability and motion) for patients who underwent arthroscopic Bankart repair compared to the Latarjet group.

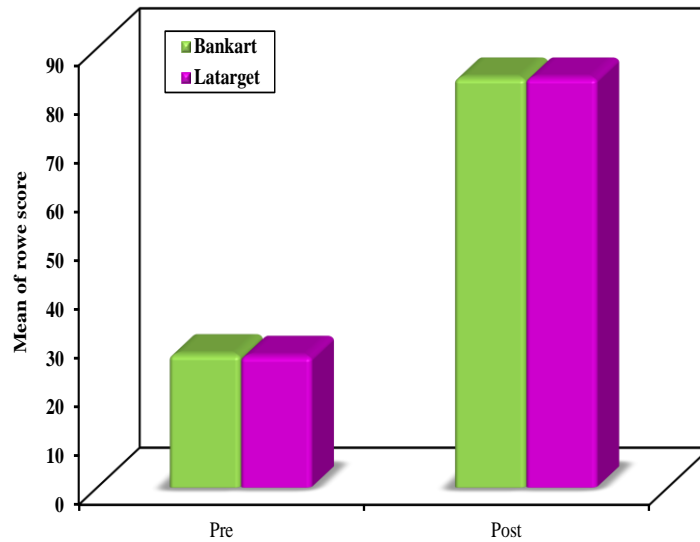


Figure 4: Comparison between the two studied groups according to final Rowe score.

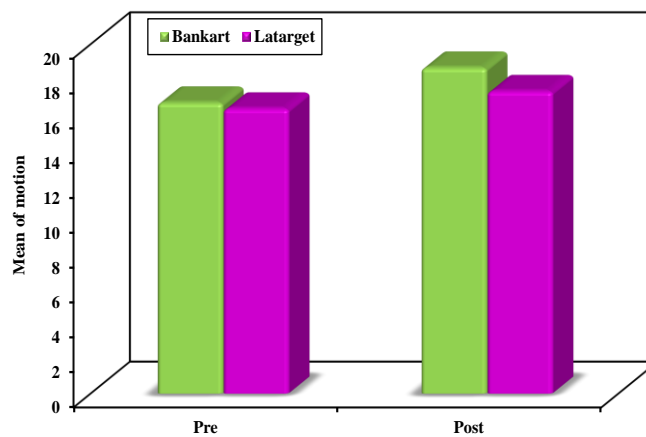


Figure 5: Comparison between the two studied groups according to Motion.

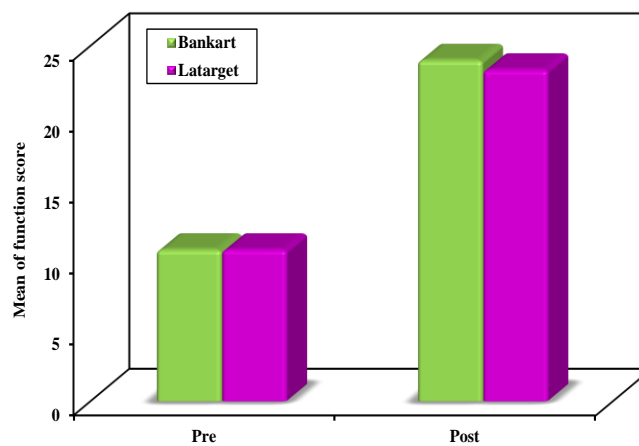


Figure 6: Comparison between the two studied groups according to Function.

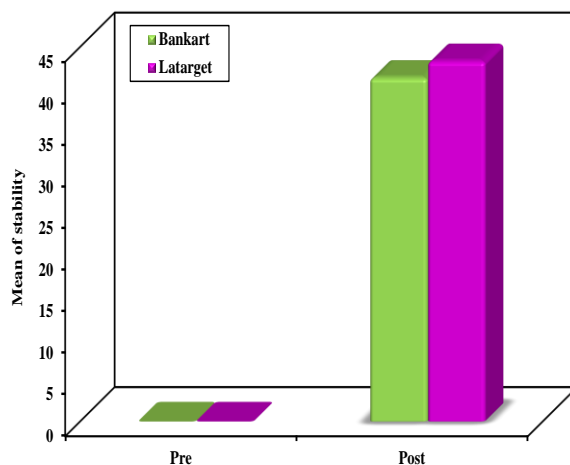


Figure 7: Comparison between the two studied groups according to Stability.

3. Postoperative return to work/sport:

The mean time to return to work/sport was 6.12 months ranging from 3.3 to 9.2 months. Eighteen patients (60%) were able to return to the same pre-injury level of work/sport. Seven patients (23.3%) patients returned to their work but with limitation. Three patients (10%) returned to their sports but not at the same pre-injury level. Two patients (6.7%) changed their work/sport.

There was a statistically significant difference between the mean time to return to work/sport for patients who underwent arthroscopic Bankart repair operation (7 months) compared to the Latarjet group (5.2 months). However, there was no difference between the two groups regarding the rate of return to work/sport.

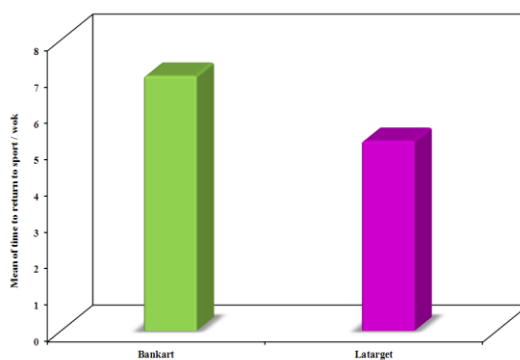


Figure 8: Comparison between the two studied groups according to time to return to work/sport.

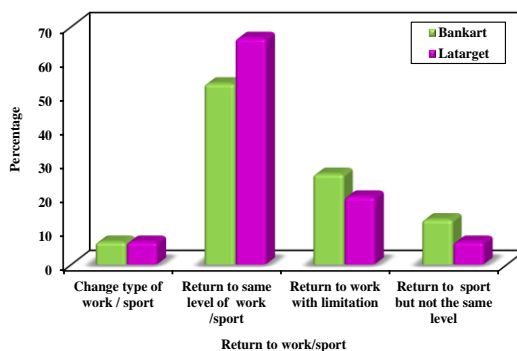


Figure 9: Comparison between the two studied groups according to rate of return to work/sport

4. Surgical time

There was a statistically significant difference between the mean surgical time for arthroscopic Bankart repair (43.33 ± 5.27 min) and Latarjet procedure (72.33 ± 10.38 min).

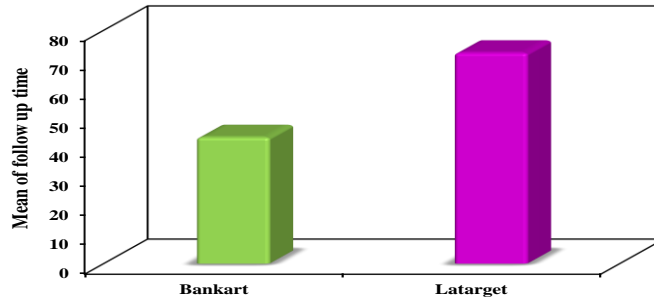


Figure 10: Relation between Type of surgery and surgical time (minutes)

5. Number of dislocations

There was no statistical significance between the number of anterior dislocations and the post-operative score in both groups.

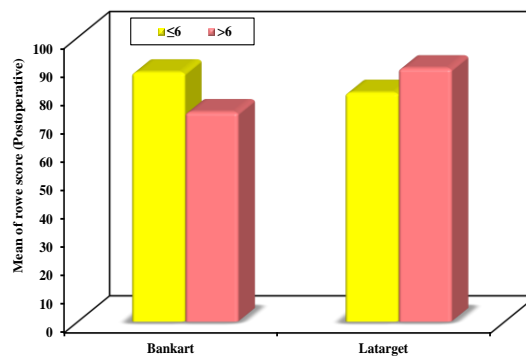


Figure 11: Relation between number of dislocations and postoperative Rowe score in both groups

6. Immobilization post reduction of first dislocation

There was no statistically significance between post reduction immobilisation and postoperative Rowe score in both groups.

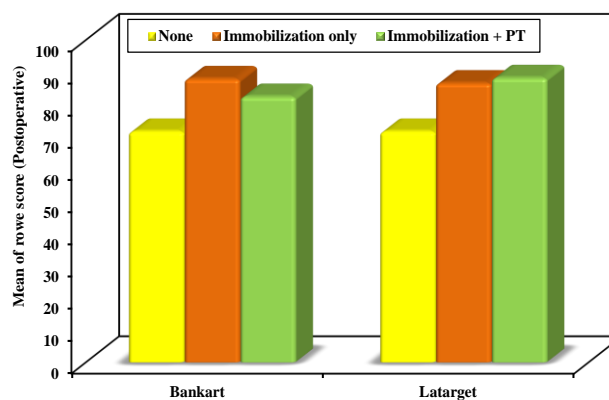


Figure 12: Relation between immobilisation and postoperative Rowe score in both groups.

Complications

There was no complications and none of the patients had recurrent dislocation.

4. DISCUSSION

Anterior shoulder instability is frequent in the young, athletic population, with high rates of 12 dislocations per 100,000 exposure. (2)

Athletes involved in collision or contact sports are more prone to high velocity impacts and repetitive positions making their shoulders at risk of injury compared to noncontact athletes.(3)

Evidence-based data support the efficacy of both; arthroscopic bankart and Latarjet, and the personal preference of the surgeon plays an important role in choosing one of these procedures over the other. Supporters of Latarjet procedure justify their choice based on a reduced recurrence rate and a superior return to the patients' pre-injury sport activity level. On the other hand, arthroscopic bankart restores the shoulder's anatomy and maintains the ROM. (16 (

In our study, we compared the results of Latarjet operation and Arthroscopic Bankart repair in 30 high demand patients including heavy labour and contact athletes with traumatic anterior shoulder instability. We excluded all the patients with glenoid bone loss > 15% , Hill-Sachs lesion > 20% of humeral articular arc as well as patients who had a previous surgery for shoulder instability. The mean follow up duration was 9.27 months \pm 2.70 (range, 6-20 months.(

There are various controversial reports in literature about the return to sports after Latarjet vs arthroscopic bankart repair. Multiple studies reported rates of 66-100% for return to the pre-injury level of competition after Bankart operation.(118-120) Similarly, several studies showed that athletes who undergo Latarjet procedure returned to the same level of competition at comparable rates of 65-96%. (18, 20, 121 (

Jeon et al (122) found no significant difference in terms of the level of return to sports between Latarjet (96.8%) and Bankart (94.1%) concluding that the surgical method doesn't have an effect on the level of post-operative return to sports. Also, Bessière et al(16) reported that 63 % of patients who underwent Bankart repair and 72 % who underwent Latarjet procedure returned to their pre-injury level, despite the difference was not statistically significant. Furthermore, a meta-analysis and systematic review done by Ialenti et al (123) showed no significant differences at the pre-injury level or at any level of return to sports for the patients treated with Latarjet procedure or arthroscopic Bankart repair .

In our study, there was no statistical significance between the rate of return to sports/work in both groups. In the Latarjet group, 10 patients (66.7%) returned to pre-injury level compared to 8 patients (53.3%) in the Bankart group.

The main finding of our study was the time to return to work/sports which was significantly lower in the Latarjet group (5.2 months) compared to the Bankart group (7 months).(

Dekker et al (124) showed no statistically significant difference in return to competition rates as well as time to return for players who underwent Latarjet procedures when compared with Bankart repairs (4.2 vs 4.6 months). Ialenti et al (123) showed in their systematic review that patients who underwent Latarjet procedure on average took around 1 month less to return to sports compared to those who underwent Bankart stabilization procedures (5.3 vs 6.1 months .(

Abdul-Rassoul et al (125) compared the amount of time for athletes to return back to sports after different surgical procedures for shoulder anterior instability. Return to sport at a mean of 5.9 months after Bankart repair done arthroscopically, 5.8 months after Latarjet done arthroscopically and 5 months after open Latarjet which is comparable to our aforementioned results .

All patients in our study were assessed according to the Rowe scoring system as regards stability, ROM and function of the shoulder. There was a statistically significant increase in the Rowe score postoperatively with mean score of 84.0 ± 15.83 compared to 27.17 ± 12.15 preoperatively. However, there was no statistical significant difference in the Rowe score postoperatively and the postoperative ROM between Bankart and Latarjet groups .

Ialenti et al (123) found in their systematic review that Rowe score was the most used patient outcome measure amongst the evaluated papers with the mean score for open bankart was 86 postoperatively compared to 79.5 for arthroscopic bankart and 82.0 for Latarjet groups concluding that there was no statistical difference among the 3 groups.

Jeon et al (122) found no significant difference in the clinical outcome in arthroscopic Bankart repair and Latarjet procedure for patients treated for recurrent anterior shoulder instability with an a borderline (15%-20%) glenoid bone defect.

Several studies reported that Latarjet procedure could lead to less limited external rotation than arthroscopic Bankart repair. Hovelius et al(126) compared their results after 17years of follow up and found that patients who underwent Latarjet procedure had an 11 degree loss in external rotation with the arm at the side, while those who underwent arthroscopic Bankart repair had 19 degree loss. In a systematic review of studies comparing Bankart repair and the Latarjet procedure by An et al(17) the mean for the calculated external rotation losses were 20.9 degree and 11.5 degree after the Bankart repair and Latarjet procedure, respectively. Jeon et al(122) showed in their study that loss of ER at the side was significantly higher in the Bankart group (13.3 degrees) compared to the Latarjet group (7.3 degrees) justifying that excessive tension of the capsule was avoided in Latarjet by re-attaching the coraco-acromial ligament to the mid portion of the anterior capsule, while the arthroscopic bankart repair increases the capsular tension by bringing the labrum and the retracted anterior capsule to their original position at the margin of the glenoid.

A couple of recent studies mentioned increased recurrent instability with arthroscopic Bankart repair specifically in young contact athletes with critical or subcritical glenoid bony loss, which has resulted in the expansion of the indications for the bone augmentation procedures as Latarjet. (2, 20)

Jeon et al(122) reported recurrence rates of 22.9 % (27 out of 118 shoulders) in the Bankart group compared to 6.5 % (2 out of 31 shoulders) in the Latarjet group at their last follow-up with the mean of 28.9 months .

On the other hand, Ialenti et al(123) found that recurrent dislocation was significantly less post Latarjet stabilization (3.5 %) in comparison to arthroscopic Bankart repair (6.6 %) and open Bankart repair (6.7.(%

In our study, there was no recurrent dislocations which may be related to the short follow up period and small number of patients included in the study.

5. CONCLUSION

The main finding of our study was the time to return to work/sports which was significantly lower in the Latarjet group (5.2 months) compared to the Bankart group (7 months). On the other hand, there was no statistical significance between the rate of return to sports/work in both groups. All patients in our study were assessed according to the Rowe scoring system as regards stability, ROM and function of the shoulder. There was a statistically significant increase in the Rowe score postoperatively with mean score of 84.0 ± 15.83 compared to 27.17 ± 12.15 preoperatively. However, there was no statistical significant difference in the postoperative ROM and Rowe score between Bankart and Latarjet groups.

Both the Latarjet procedure and the arthroscopic Bankart repair revealed satisfactory clinical outcomes with nearly similar rate of return to sports/work in high demand patients with recurrent anterior glenohumeral dislocation.

Latarjet procedure is considered more invasive and non-anatomical procedure, however it is less costly with shorter time to return to sports/work compared to Bankart.

Evidence-based data support both procedures, thus the personal preference of the surgeon will always play a paramount role in choosing one of these procedures over the other.

REFERENCES

- [1] Hovelius L, Körner L, Lundberg B, Akermark C, Herberts P, Wredmark T, et al. The coracoid transfer for recurrent dislocation of the shoulder. Technical aspects of the Bristow-Latarjet procedure. *J Bone Joint Surg Am* 1983; 65(7):926-34.
- [2] Owens BD, Agel J, Mountcastle SB, Cameron KL, Nelson BJ. Incidence of glenohumeral instability in collegiate athletics. *Am J Sports Med* 2009; 37(9):1750-4.
- [3] Mazzocca AD, Brown FM, Jr., Carreira DS, Hayden J, Romeo AA. Arthroscopic anterior shoulder stabilization of collision and contact athletes. *Am J Sports Med* 2005; 33(1):52-60.
- [4] Bankart ASB. The pathology and treatment of recurrent dislocation of the shoulder-joint. *Br J Surg* 1938; 26(101):23-9.
- [5] Freedman KB, Smith AP, Romeo AA, Cole BJ, Bach BR, Jr. Open Bankart repair versus arthroscopic repair with transglenoid sutures or bioabsorbable tacks for Recurrent Anterior instability of the shoulder: a meta-analysis. *Am J Sports Med* 2004; 32(6):1520-7.

- [6] Lenters TR, Franta AK, Wolf FM, Leopold SS, Matsen FA, 3rd. Arthroscopic compared with open repairs for recurrent anterior shoulder instability. A systematic review and meta-analysis of the literature. *J Bone Joint Surg Am* 2007; 89(2):244-54.
- [7] Hobby J, Griffin D, Dunbar M, Boileau P. Is arthroscopic surgery for stabilisation of chronic shoulder instability as effective as open surgery? A systematic review and meta-analysis of 62 studies including 3044 arthroscopic operations. *J Bone Joint Surg Br* 2007; 89(9):1188-96.
- [8] Sugaya H, Moriishi J, Dohi M, Kon Y, Tsuchiya A. Glenoid rim morphology in recurrent anterior glenohumeral instability. *J Bone Joint Surg Am* 2003; 85(5):878-84.
- [9] Edwards TB, Boulahia A, Walch G. Radiographic analysis of bone defects in chronic anterior shoulder instability. *Arthroscopy* 2003; 19(7):732-9.
- [10] Itoi E, Lee SB, Berglund LJ, Berge LL, An KN. The effect of a glenoid defect on anteroinferior stability of the shoulder after Bankart repair: a cadaveric study. *J Bone Joint Surg Am* 2000; 82(1):35-46.
- [11] Latarjet M. Treatment of recurrent dislocation of the shoulder. *Lyon Chir* 1954; 49(8):994-7.
- [12] Patte D, Debeyre J. Luxations récidivantes de l'épaule. *Encycl Med Chir Paris-Technique chirurgicale* 1980; 44265(4).
- [13] Boileau P, Mercier N, Roussanne Y, Thélu C, Old J. Arthroscopic Bankart-Bristow-Latarjet procedure: the development and early results of a safe and reproducible technique. *Arthroscopy* 2010; 26(11):1434-50.
- [14] Burkhart SS, De Beer JF, Barth JR, Cresswell T, Roberts C, Richards DP. Results of modified Latarjet reconstruction in patients with anteroinferior instability and significant bone loss. *Arthroscopy* 2007; 23(10):1033-41.
- [15] Wellmann M, de Ferrari H, Smith T, Petersen W, Siebert CH, Agneskirchner JD, et al. Biomechanical investigation of the stabilization principle of the Latarjet procedure. *Arch Orthop Trauma Surg* 2012; 132(3):377-86.
- [16] Bessière C, Trojani C, Carles M, Mehta SS, Boileau P. The open Latarjet procedure is more reliable in terms of shoulder stability than arthroscopic Bankart repair. *Clin Orthop Relat Res* 2014; 472(8):2345-51.
- [17] An VV, Sivakumar BS, Phan K, Trantalis J. A systematic review and meta-analysis of clinical and patient-reported outcomes following two procedures for recurrent traumatic anterior instability of the shoulder: Latarjet procedure vs. Bankart repair. *J Shoulder Elbow Surg* 2016; 25(5):853-63.
- [18] Beranger JS, Klouche S, Bauer T, Demoures T, Hardy P. Anterior shoulder stabilization by Bristow-Latarjet procedure in athletes: return-to-sport and functional outcomes at minimum 2-year follow-up. *Eur J Orthop Surg Traumatol* 2016; 26(3):277-82.
- [19] Baverel L, Colle PE, Saffarini M, Anthony Odri G, Barth J. Open Latarjet Procedures Produce Better Outcomes in Competitive Athletes Compared With Recreational Athletes: A Clinical Comparative Study of 106 Athletes Aged Under 30 Years. *Am J Sports Med* 2018; 46(6):1408-15.
- [20] Privitera DM, Sinz NJ, Miller LR, Siegel EJ, Solberg MJ, Daniels SD, et al. Clinical Outcomes Following the Latarjet Procedure in Contact and Collision Athletes. *J Bone Joint Surg Am* 2018; 100(6):459-65.
- [21] Quillen DM, Wuchner M, Hatch RL. Acute shoulder injuries. *Am Fam Physician* 2004; 70(10):1947-54.
- [22] Jenkins DB, Hollinshead WH. *Hollinshead's Functional Anatomy of the Limbs and Back*. Philadelphia, Pa: WB Saunders; 1998. 59-90.
- [23] Rockwood C, Matsen F. *The Shoulder*. Philadelphia, Pa: WB Saunders; 1998. 338-63.
- [24] Moore KL, Agur AMR. *Upper limb. Essential Clinical Anatomy*. Philadelphia, Pa: Lippincott Williams & Wilkins; 2007. 407-90.

International Journal of Novel Research in Life Sciences

 Vol. 10, Issue 1, pp: (1-22), Month: January - February 2023, Available at: www.noveltyjournals.com

- [25] Blasier RB, Carpenter JE, Huston LJ. Shoulder proprioception. Effect of joint laxity, joint position, and direction of motion. *Orthop Rev* 1994; 23(1):45-50.
- [26] Tibone JE, Fechter J, Kao JT. Evaluation of a proprioception pathway in patients with stable and unstable shoulders with somatosensory cortical evoked potentials. *J Shoulder Elbow Surg* 1997; 6(5):440-3.
- [27] Bigliani LU, Kelkar R, Flatow EL, Pollock RG, Mow VC. Glenohumeral stability. Biomechanical properties of passive and active stabilizers. *Clin Orthop Relat Res* 1996; (330):13-30.
- [28] Soslowky LJ, Flatow EL, Bigliani LU, Mow VC. Articular geometry of the glenohumeral joint. *Clin Orthop Relat Res* 1992; (285):181-90.
- [29] Itoi E, Morrey BF, Kai-Nan A. Biomechanics of the shoulder. In: Williams D (ed). *Rockwood and Matsen S The Shoulder* 4th Edition. 4th ed. Philadelphia: Elsevier Saunders; 2009. 213-65.
- [30] Howell SM, Galinat BJ. The glenoid-labral socket. A constrained articular surface. *Clin Orthop Relat Res* 1989; (243):122-5.
- [31] O'Brien SJ, Voos JE, Neviaser AS, Drakos MC. Developmental anatomy of the shoulder and anatomy of the glenohumeral joint. In: Rockwood CJ, Matsen F (eds). *The shoulder*. 4th ed. Philadelphia: Elsevier Saunders; 2009.1-31.
- [32] Cole BJ, Rios CG, Mazzocca AD, Warner JJP. Anatomy, Biomechanics, and Pathophysiology of Glenohumeral Instability. In: Iannotti JP, Williams GR (eds). *Disorders of the Shoulder: Diagnosis and Management*. 2nd ed: Lippincott Williams & Wilkins; 2007. 281-312.
- [33] Apostolakos J, Yang JS, Hoberman AR, Shoji M, Weinreb JH, Voss A, et al. Glenoid Labrum. In: Bain GI, Itoi E, Di Giacomo G, Sugaya H (eds). *Normal and Pathological Anatomy of the Shoulder*. Berlin, Heidelberg: Springer Berlin Heidelberg; 2015. 83-91.
- [34] Cooper DE, Arnoczky SP, O'Brien SJ, Warren RF, DiCarlo E, Allen AA. Anatomy, histology, and vascularity of the glenoid labrum. An anatomical study. *J Bone Joint Surg Am* 1992; 74(1):46-52.
- [35] Williams MM, Snyder SJ, Buford D. The Buford complex--the "cord-like" middle glenohumeral ligament and absent anterosuperior labrum complex: a normal anatomic capsulolabral variant. *Arthroscopy* 1994; 10(3):241-7.
- [36] Flatow EL, Warner JJP. Instability of the shoulder: Complex problems and failed repairs: Part 1. Relevant biomechanics, multidirectional instability, and severe loss of glenoid and humeral bone. *J Bone Joint Surg* 1998; 80(1):122-40.
- [37] Vita AD. Glenohumeral Joint (Muscle-Tendon). In: Giacomo GD, Pouliart N, Costantini A (eds). *Atlas of Functional Shoulder Anatomy*. Verlag Italia Springer; 2008. 60-108.
- [38] Jerry SS, Levy JC, Iannotti JP. Diagnosis of Glenohumeral Instability. In: Williams GR (ed). *Disorders of the Shoulder: Diagnosis and Management*. Lippincott Williams & Wilkins; 2007; 339-67.
- [39] O'Connell PW, Nuber GW, Mileski RA, Lautenschlager E. The contribution of the glenohumeral ligaments to anterior stability of the shoulder joint. *Am J Sports Med* 1990; 18(6):579-84.
- [40] Jerry SS, Levy JC, Iannotti JP. Diagnosis of Glenohumeral Instability. In: Williams GR (ed). *Disorders of the Shoulder: Diagnosis and Management*. Lippincott Williams & Wilkins; 2007. 339-67.
- [41] Ferrari DA. Capsular ligaments of the shoulder. Anatomical and functional study of the anterior superior capsule. *Am J Sports Med* 1990; 18(1):20-4.
- [42] Warner JJ, Deng XH, Warren RF, Torzilli PA. Static capsuloligamentous restraints to superior-inferior translation of the glenohumeral joint. *Am J Sports Med* 1992; 20(6):675-85.
- [43] O'Brien SJ, Neves MC, Arnoczky SP, Rozbruch SR, Dicarlo EF, Warren RF, et al. The anatomy and histology of the inferior glenohumeral ligament complex of the shoulder. *Am J Sports Med* 1990; 18(5):449-56.

International Journal of Novel Research in Life Sciences

 Vol. 10, Issue 1, pp: (1-22), Month: January - February 2023, Available at: www.noveltyjournals.com

- [44] Ticker JB, Bigliani LU, Soslowky LJ, Pawluk RJ, Flatow EL, Mow VC. Inferior glenohumeral ligament: geometric and strain-rate dependent properties. *J Shoulder Elbow Surg* 1996; 5(4):269-79.
- [45] Lippitt SB, Vanderhoof JE, Harris SL, Sidles JA, Harryman DT, 2nd, Matsen FA, 3rd. Glenohumeral stability from concavity-compression: A quantitative analysis. *J Shoulder Elbow Surg* 1993; 2(1):27-35.
- [46] Rodosky MW, Harner CD, Fu FH. The role of the long head of the biceps muscle and superior glenoid labrum in anterior stability of the shoulder. *Am J Sports Med* 1994; 22(1):121-30.
- [47] Matsen F, Lippitt S, Bertlesen A. Glenohumeral Instability. In: Lynn CA (ed). *The shoulder*. 4th ed. Philadelphia: Elsevier Saunders; 2009. 617-770.
- [48] Emery RJ, Mullaji AB. Glenohumeral joint instability in normal adolescents. Incidence and significance. *J Bone Joint Surg Br* 1991; 73(3):406-8.
- [49] Gerber C, Nyffeler RW. Classification of glenohumeral joint instability. *Clin Orthop Relat Res* 2002; (400):65-76.
- [50] Rowe CR, Pierce DS, Clark JG. Voluntary dislocation of the shoulder. A preliminary report on a clinical, electromyographic, and psychiatric study of twenty-six patients. *J Bone Joint Surg Am* 1973; 55(3):445-60.
- [51] Silliman JF, Hawkins RJ. Classification and physical diagnosis of instability of the shoulder. *Clin Orthop Relat Res* 1993; (291):7-19.
- [52] Hawkins RJ, Neer CS, Pianta RM, Mendoza FX. Locked posterior dislocation of the shoulder. *J Bone Joint Surg Am* 1987; 69(1):9-18.
- [53] Thomas SC, Matsen FA. An approach to the repair of avulsion of the glenohumeral ligaments in the management of traumatic anterior glenohumeral instability. *J Bone Joint Surg Am* 1989; 71(4):506-13.
- [54] Rockwood CJ. Subluxation of the shoulder the classification, diagnosis, and treatment. *Orthop Trans* 1979;4:306-13.
- [55] Marquardt B, Witt KA, Liem D, Steinbeck J, Pözl W. Arthroscopic Bankart repair in traumatic anterior shoulder instability using a suture anchor technique. *Arthroscopy* 2006; 22(9):931-6.
- [56] Kralinger FS, Golser K, Wischatta R, Wambacher M, Sperner G. Predicting recurrence after primary anterior shoulder dislocation. *Am J Sports Med* 2002; 30(1):116-20.
- [57] Neviaser RJ, Neviaser TJ, Neviaser JS. Anterior dislocation of the shoulder and rotator cuff rupture. *Clin Orthop Relat Res* 1993; (291):103-6.
- [58] Gumina S, Postacchini F. Anterior dislocation of the shoulder in elderly patients. *J Bone Joint Surg Br* 1997; 79(4):540-3.
- [59] Kim SH. Pathoanatomy of Glenohumeral Instability. In: Bain GI, Itoi E, Di Giacomo G, Sugaya H (eds). *Normal and Pathological Anatomy of the Shoulder*. Berlin, Heidelberg: Springer Berlin Heidelberg; 2015. 115-22.
- [60] Speer KP, Deng X, Borrero S, Torzilli PA, Altchek DA, Warren RF. Biomechanical evaluation of a simulated Bankart lesion. *J Bone Joint Surg Am* 1994; 76(12):1819-26.
- [61] Neviaser TJ. The anterior labroligamentous periosteal sleeve avulsion lesion: a cause of anterior instability of the shoulder. *Arthroscopy* 1993; 9(1):17-21.
- [62] Ozbaydar M, Elhassan B, Diller D, Massimini D, Higgins LD, Warner JJ. Results of arthroscopic capsulolabral repair: Bankart lesion versus anterior labroligamentous periosteal sleeve avulsion lesion. *Arthroscopy* 2008; 24(11):1277-83.
- [63] Saba L, De Filippo M. MR arthrography evaluation in patients with traumatic anterior shoulder instability. *J Orthop* 2017; 14(1):73-6.

International Journal of Novel Research in Life Sciences

 Vol. 10, Issue 1, pp: (1-22), Month: January - February 2023, Available at: www.noveltyjournals.com

- [64] Johnson LL. Techniques of anterior glenohumeral ligament repair. In: Johnson LL (ed). *Arthroscopic Surgery: Principles & Practice*. 3rd ed: St. Louis: CV Mosby; 1986. 1405-20.
- [65] John M, Nebelung W, Röpke M, Ender SA, Urbach D. Arthroscopic labrum reconstruction with capsular shift in anterior shoulder instability: improved midterm results by using a standardized supraticipital camera position. *Arthroscopy* 2007; 23(7):688-95.
- [66] Bigliani LU, Kurzweil PR, Schwartzbach CC, Wolfe IN, Flatow EL. Inferior capsular shift procedure for anterior-inferior shoulder instability in athletes. *Am J Sports Med* 1994; 22(5):578-84.
- [67] Bokor DJ, Conboy VB, Olson C. Anterior instability of the glenohumeral joint with humeral avulsion of the glenohumeral ligament. A review of 41 cases. *J Bone Joint Surg Br* 1999; 81(1):93-6.
- [68] Oberlander MA, Morgan BE, Visotsky JL. The BHAGL lesion: a new variant of anterior shoulder instability. *Arthroscopy* 1996; 12(5):627-33.
- [69] Stoller DW, Wolf EM, Li AE. The Shoulder. In: Stoller DW (ed). *Magnetic Resonance Imaging in Orthopaedics and Sports Medicine*. 3rd ed. Philadelphia: Lippincott Williams & Wilkins; 2007 1142-45.
- [70] Hill HA, Sachs MD. The grooved defect of the humeral head: a frequently unrecognized complication of dislocations of the shoulder joint. *Radiology* 1940; 35(6):690-700.
- [71] Owens BD, Nelson BJ, Duffey ML, Mountcastle SB, Taylor DC, Cameron KL, et al. Pathoanatomy of first-time, traumatic, anterior glenohumeral subluxation events. *J Bone Joint Surg Am* 2010; 92(7):1605-11.
- [72] Griffith JF, Antonio GE, Yung PS, Wong EM, Yu AB, Ahuja AT, et al. Prevalence, pattern, and spectrum of glenoid bone loss in anterior shoulder dislocation: CT analysis of 218 patients. *AJR Am J Roentgenol* 2008; 190(5):1247-54.
- [73] Grant JA, Sekiya J, K. Shoulder instability: classification and diagnosis. In: Zuckerman JD, Iannotti JP, Miniaci A, Williams GR (eds). *Disorders of the Shoulder: Diagnosis and Management*: Lippincott Williams & Wilkins; 2014.
- [74] Ellenbecker TS. *Clinical Examination of the Shoulder*. St. Louis, Mo: WB Saunders; 2004. 54-9.
- [75] Wilk KE, Macrina LC. Nonoperative and postoperative rehabilitation for glenohumeral instability. *Clin Sports Med* 2013; 32(4):865-914.
- [76] Matsen F, Lippitt S, Bertlesen A. Glenohumeral Instability In: Lynn CA (ed). *The shoulder*. 4th ed. Philadelphia: Elsevier Saunders; 2009. 617-770.
- [77] Arcand MA, Reider B. Shoulder and Upper Arm. In: Joseph B (ed). *The Orthopaedics Physical Examination*. 2nd ed. Philadelphia: Elsevier Saunders; 2005. 17-66.
- [78] Michael Codsi, Jesse McCarron, John J. Brems. Clinical Evaluation of Shoulder Problems In: Rockwood CJ, Matsen F (eds). *The shoulder*. 4th ed. Philadelphia: Elsevier Saunders; 2009. 154-76.
- [79] Provencher MT, Bhatia S, Ghodadra NS, Grumet RC, Bach BR, Jr., Dewing CB, et al. Recurrent shoulder instability: current concepts for evaluation and management of glenoid bone loss. *J Bone Joint Surg Am* 2010; 92(Suppl 2):133-51.
- [80] Murachovsky J, Bueno RS, Nascimento LG, Almeida LH, Strose E, Castiglia MT, et al. Calculating anterior glenoid bone loss using the Bernageau profile view. *Skeletal Radiol* 2012; 41(10):1231-7.
- [81] Garth WP, Jr., Slappeg CE, Ochs CW. Roentgenographic demonstration of instability of the shoulder: the apical oblique projection. A technical note. *J Bone Joint Surg Am* 1984; 66(9):1450-3.
- [82] Provencher MT, Frank RM, Leclere LE, Metzger PD, Ryu JJ, Bernhardson A, et al. The Hill-Sachs lesion: diagnosis, classification, and management. *J Am Acad Orthop Surg* 2012; 20(4):242-52.
- [83] Kwon YW, Powell KA, Yum JK, Brems JJ, Iannotti JP. Use of three-dimensional computed tomography for the analysis of the glenoid anatomy. *J Shoulder Elbow Surg* 2005; 14(1):85-90.

- [84] Sanders TG, Morrison WB, Miller MD. Imaging techniques for the evaluation of glenohumeral instability. *Am J Sports Med* 2000; 28(3):414-34.
- [85] Saliken DJ, Bornes TD, Bouliane MJ, Sheps DM, Beaupre LA. Imaging methods for quantifying glenoid and Hill-Sachs bone loss in traumatic instability of the shoulder: a scoping review. *BMC Musculoskelet Disord* 2015; 16:164.
- [86] Hamamoto JT, Leroux T, Chahla J, Bhatia S, Higgins JD, Romeo AA, et al. Assessment and Evaluation of Glenoid Bone Loss. *Arthrosc Tech* 2016; 5(4):e947-e51.
- [87] Kralinger F, Aigner F, Longato S, Rieger M, Wambacher M. Is the bare spot a consistent landmark for shoulder arthroscopy? A study of 20 embalmed glenoids with 3-dimensional computed tomographic reconstruction. *Arthroscopy* 2006; 22(4):428-32.
- [88] Gyftopoulos S, Yemin A, Mulholland T, Bloom M, Storey P, Geppert C, et al. 3DMR osseous reconstructions of the shoulder using a gradient-echo based two-point Dixon reconstruction: a feasibility study. *Skeletal Radiol* 2013; 42(3):347-52.
- [89] Stillwater L, Koenig J, Maycher B, Davidson M. 3D-MR vs. 3D-CT of the shoulder in patients with glenohumeral instability. *Skeletal Radiol* 2017; 46(3):325-31.
- [90] Maio M, Sarmiento M, Moura N, Cartucho A. How to measure a Hill-Sachs lesion: a systematic review. *EFORT Open Rev* 2019; 4(4):151-7.
- [91] Chen AL, Hunt SA, Hawkins RJ, Zuckerman JD. Management of bone loss associated with recurrent anterior glenohumeral instability. *Am J Sports Med* 2005; 33(6):912-25.
- [92] Rowe CR, Zarins B, Ciullo JV. Recurrent anterior dislocation of the shoulder after surgical repair. Apparent causes of failure and treatment. *J Bone Joint Surg Am* 1984; 66(2):159-68.
- [93] Richards RD, Sartoris DJ, Pathria MN, Resnick D. Hill-Sachs lesion and normal humeral groove: MR imaging features allowing their differentiation. *Radiology* 1994; 190(3):665-8.
- [94] Flatow EL, Warner JJ. Instability of the shoulder: complex problems and failed repairs: Part I. Relevant biomechanics, multidirectional instability, and severe glenoid loss. *Instr Course Lect* 1998; 47:97-112.
- [95] Assunção JH, Gracitelli ME, Borgo GD, Malavolta EA, Bordalo-Rodrigues M, Ferreira Neto AA. Tomographic evaluation of Hill-Sachs lesions: is there a correlation between different methods of measurement? *Acta Radiol* 2017; 58(1):77-83.
- [96] Ozaki R, Nakagawa S, Mizuno N, Mae T, Yoneda M. Hill-sachs lesions in shoulders with traumatic anterior instability: evaluation using computed tomography with 3-dimensional reconstruction. *Am J Sports Med* 2014; 42(11):2597-605.
- [97] Cho SH, Cho NS, Rhee YG. Preoperative analysis of the Hill-Sachs lesion in anterior shoulder instability: how to predict engagement of the lesion. *Am J Sports Med* 2011; 39(11):2389-95.
- [98] Di Giacomo G, Itoi E, Burkhart SS. Evolving concept of bipolar bone loss and the Hill-Sachs lesion: from "engaging/non-engaging" lesion to "on-track/off-track" lesion. *Arthroscopy* 2014; 30(1):90-8.
- [99] Burns DM, Chahal J, Shahrokhi S, Henry P, Wasserstein D, Whyne C, et al. Diagnosis of Engaging Bipolar Bone Defects in the Shoulder Using 2-Dimensional Computed Tomography: A Cadaveric Study. *Am J Sports Med* 2016; 44(11):2771-7.
- [100] Taylor DC, Krasinski KL. Adolescent shoulder injuries: consensus and controversies. *Instr Course Lect* 2009; 58:281-92.
- [101] Rhee YG, Cho NS, Cho SH. Traumatic anterior dislocation of the shoulder: factors affecting the progress of the traumatic anterior dislocation. *Clin Orthop Surg* 2009; 1(4):188-93.

- [102] Garcia GH, Liu JN, Dines DM, Dines JS. Effect of bone loss in anterior shoulder instability. *World J Orthop* 2015; 6(5):421-33.
- [103] Wang L, Liu Y, Su X, Liu S. A Meta-Analysis of Arthroscopic versus Open Repair for Treatment of Bankart Lesions in the Shoulder. *Med Sci Monit* 2015; 21:3028-35.
- [104] Helfet AJ. Coracoid transplantation for recurring dislocation of the shoulder. *J Bone Joint Surg Br* 1958; 40-b(2):198-202.
- [105] Burkhart SS, De Beer JF, Barth JRH, Criswell T, Roberts C, Richards DP. Results of modified Latarjet reconstruction in patients with anteroinferior instability and significant bone loss. *Arthroscopy* 2007; 23(10):1033-41.
- [106] Lafosse L, Boyle S, Gutierrez-Aramberri M, Shah A, Meller R. Arthroscopic latarjet procedure. *Orthop Clin North Am* 2010; 41(3):393-405.
- [107] Burkhart SS, De Beer JF. Traumatic glenohumeral bone defects and their relationship to failure of arthroscopic Bankart repairs: significance of the inverted-pear glenoid and the humeral engaging Hill-Sachs lesion. *Arthroscopy* 2000; 16(7):677-94.
- [108] Boileau P, Villalba M, Héry JY, Balg F, Ahrens P, Neyton L. Risk factors for recurrence of shoulder instability after arthroscopic Bankart repair. *J Bone Joint Surg Am* 2006; 88(8):1755-63.
- [109] Balg F, Boileau P. The instability severity index score. A simple pre-operative score to select patients for arthroscopic or open shoulder stabilisation. *J Bone Joint Surg Br* 2007; 89(11):1470-7.
- [110] Lemmex D, Cárdenas G, Ricks M, Woodmass J, Chelli M, Boileau P. Arthroscopic Management of Anterior Glenoid Bone Loss. *JBJS Rev* 2020; 8(2):e0049.
- [111] Shaha JS, Cook JB, Song DJ, Rowles DJ, Bottoni CR, Shaha SH, et al. Redefining "Critical" Bone Loss in Shoulder Instability: Functional Outcomes Worsen With "Subcritical" Bone Loss. *Am J Sports Med* 2015; 43(7):1719-25.
- [112] Yamamoto N, Kawakami J, Hatta T, Itoi E. Effect of subcritical glenoid bone loss on activities of daily living in patients with anterior shoulder instability. *Orthop Traumatol Surg Res* 2019; 105(8):1467-70.
- [113] Kurokawa D, Yamamoto N, Nagamoto H, Omori Y, Tanaka M, Sano H, et al. The prevalence of a large Hill-Sachs lesion that needs to be treated. *J Shoulder Elbow Surg* 2013; 22(9):1285-9.
- [114] Yamamoto N, Itoi E, Abe H, Minagawa H, Seki N, Shimada Y, et al. Contact between the glenoid and the humeral head in abduction, external rotation, and horizontal extension: a new concept of glenoid track. *J Shoulder Elbow Surg* 2007; 16(5):649-56.
- [115] Di Giacomo G, Piscitelli L, Pugliese M. The role of bone in glenohumeral stability. *EFORT Open Rev* 2018; 3(12):632-40.
- [116] Provencher MT, Ferrari MB, Sanchez G, Anavian J, Akamefula R, LeBus GF. Current Treatment Options for Glenohumeral Instability and Bone Loss: A Critical Analysis Review. *JBJS Rev* 2017; 5(7):e6.
- [117] Rowe CR, Patel D, Southmayd WW. The Bankart procedure: a long-term end-result study. *J Bone Joint Surg Am* 1978; 60(1):1-16.
- [118] Memon M, Kay J, Cadet ER, Shahsavari S, Simunovic N, Ayeni OR. Return to sport following arthroscopic Bankart repair: a systematic review. *J Shoulder Elbow Surg* 2018; 27(7):1342-7.
- [119] Robins RJ, Daruwalla JH, Gamradt SC, McCarty EC, Dragoo JL, Hancock RE, et al. Return to Play After Shoulder Instability Surgery in National Collegiate Athletic Association Division I Intercollegiate Football Athletes. *Am J Sports Med* 2017; 45(10):2329-35.
- [120] Saper MG, Milchtein C, Zondervan RL, Andrews JR, Ostrander RV, 3rd. Outcomes After Arthroscopic Bankart Repair in Adolescent Athletes Participating in Collision and Contact Sports. *Orthop J Sports Med* 2017; 5(3):2325967117697950.

International Journal of Novel Research in Life Sciences

Vol. 10, Issue 1, pp: (1-22), Month: January - February 2023, Available at: www.noveltyjournals.com

- [121] Neyton L, Young A, Dawidziak B, Visona E, Hager JP, Fournier Y, et al. Surgical treatment of anterior instability in rugby union players: clinical and radiographic results of the Latarjet-Patte procedure with minimum 5-year follow-up. *J Shoulder Elbow Surg* 2012; 21(12):1721-7.
- [122] Jeon YS, Jeong HY, Lee DK, Rhee YG. Borderline Glenoid Bone Defect in Anterior Shoulder Instability: Latarjet Procedure Versus Bankart Repair. *Am J Sports Med* 2018; 46(9):2170-6.
- [123] Ialenti MN, Mulvihill JD, Feinstein M, Zhang AL, Feeley BT. Return to Play Following Shoulder Stabilization: A Systematic Review and Meta-analysis. *Orthop J Sports Med* 2017; 5(9):2325967117726055.
- [124] Dekker TJ, Goldenberg B, Lacheta L, M PH, Millett PJ. Anterior Shoulder Instability in the Professional Athlete: Return to Competition, Time to Return, and Career Length. *Orthop J Sports Med* 2020; 8(11):2325967120959728.
- [125] Abdul-Rassoul H, Galvin JW, Curry EJ, Simon J, Li X. Return to Sport After Surgical Treatment for Anterior